Andrew K. Roorda, M.D., Series Editor

The Evolution of Enteroscopy to Spiral Enteroscopy

Disaya Chavalitdhamrong

Rome Jutabha

The diagnosis and treatment of small bowel diseases has historically proven difficult and challenging for gastroenterologists. Although sonde and push enteroscopy were developed first, the former is time-consuming and uncomfortable and the latter limits examination to the proximal jejunum. Intraoperative enteroscopy, which was once considered the gold standard of enteroscopy, has largely been replaced by newer less invasive techniques. Capsule endoscopy provides a thorough examination of the small bowel but it does not allow for therapeutic interventions. Balloon-assisted enteroscopy was developed for complete examination of the small bowel and therapeutic interventions. Spiral enteroscopy has emerged as a viable alternative to balloon-assisted enteroscopy. It is a safe, effective, and relatively rapid endoscopic technique for diagnostic investigations and therapeutic interventions of small bowel pathology. This article reviews the milestone technologies of enteroscopy highlighting the latest developed spiral enteroscopy.

INTRODUCTION

Endoscopic diagnosis and treatment of small bowel conditions is a challenging area for gastroenterologists. Until recently, it was not possible to access most of the small bowel using endoscopic techniques without concomitant surgery. Capsule endoscopy and balloon-assisted enteroscopy thus represent decisive breakthroughs in this field. Capsule endoscopy allows endoscopic visualization of the entire small bowel but lacks the ability to obtain histological samples and perform endoscopic treatments. With the development of balloon-assisted enteroscopy and most recently, spiral enteroscopy, endoscopic diagnosis and treatment of the entire small intestine are now feasible without operative intervention. As indications expand and caseloads grow, it is important for gastroenterologists to know how these procedures are done and to be familiar with their potential complications.

Disaya Chavalitdhamrong, M.D. and Rome Jutabha, M.D., David Geffen School of Medicine at University of California, Los Angeles, California, USA.

THE EVOLUTION OF ENTEROSCOPY

Intraoperative enteroscopy (IOE) was initially performed in the 1950s with a rigid sigmoidoscope passed through an operative laparotomy. By the 1970s,

fiberoptic endoscopes were used for IOE (1). IOE has a high diagnostic yield but has largely been replaced because of its high complication rate, need for a surgeon as well as an endoscopist, and postprocedural hospital stay. Sonde enteroscopy was introduced in 1986 as an alternative to IOE, but it was eventually abandoned because it was labor intensive for the endoscopist and uncomfortable for the patient. Push enteroscopy (PE) is limited to the diagnosis and treatment of proximal small bowel conditions due to scope looping which hinders scope advancement and causes patient discomfort. To overcome these obstacles, double-balloon enteroscopy (DBE) was introduced in 2001. It uses the combination of an endoscope and an overtube and involves the serial inflation and deflation of balloons, which facilitate scope advancement. Recently, single-balloon enteroscopy (SBE) was developed to eliminate the requirement of inflating and deflating two balloons. However, balloon-assisted enteroscopy requires a long learning curve and involves a lengthy procedure time; especially those performed via the retrograde approach. Therefore, spiral enteroscopy was developed as a simpler and relatively faster alternative.

TYPES OF SMALL BOWEL ENTEROSCOPY

1. Enteroscopy Using a Colonoscope

The small bowel may be examined using a standard adult or a pediatric colonoscope. Using a colonoscope, with the aid of abdominal pressure, and with a change of position of the patient, up to 60 cm of small bowel beyond the ligament of Treitz can be examined.

2. Sonde Enteroscopy

The sonde fiberoptic enteroscope has a working length of 250–400 cm, and is passed orally or nasally (2). It is advanced into the duodenum with the aid of another orally passed endoscope and propelled through the small bowel by peristalsis. The main disadvantages are lack of tip deflection, absence of a biopsy channel, and lengthy procedure time (from 4–6 hours).

3. Push Enteroscopy

In PE, a colonoscope, pediatric colonoscope, or push enteroscope can be used. Advanced skill or training is not typically required to perform this procedure. Push endoscopes are 2–2.5 m in length and may be used in the combination with an overtube (3). The procedure is performed under conscious sedation and takes between 15 and 45 minutes. PE is capable of reaching the proximal jejunum but rarely reaches the mid-jejunum. After traversing the curve of the second part of the duodenum, the enteroscope is straightened to reduce any loops formed in the stomach and is then pushed to the maximum length of insertion. Use of an overtube may increase the depth of insertion (4) but complications such as mucosal stripping, bowel perforations, pharyngeal tear, pancreatitis and Mallory–Weiss tear have been reported and may limit its application. The overall complication rate from PE is approximately 1% (5). Care must be taken to avoid trauma to the thin-walled duodenum and jejunum during advancement of the relatively stiff enteroscope.

4. Intraoperative Enteroscopy

Although IOE is practiced less frequently, it still has a role in the management of lesions that may not be approachable by other endoscopic means and in the guidance of surgical management (6). Although colonoscopes are routinely used, enteroscopes may also be used. This procedure is performed in tandem by an endoscopist and a surgeon. The introductory route is chosen according to the location of the suspected pathology. The scope may be introduced in an anterograde or retrograde fashion, or through surgically created anatomy, using a sterile plastic sheath placed over the instrument. In the anterograde technique, the scope is passed into the proximal jejunum before the laparotomy as it may be difficult to advance the instrument around the ligament of Trietz once the laparotomy is performed. The surgeon grasps the endoscope tip and holds a short segment of bowel to allow endoscopic inspection during intubation. External mucosal lesions can be identified by transillumination. After an area is examined, the small bowel is pleated onto the shaft of the endoscope, and the next section of bowel is examined. The surgeon marks any identified lesions with a suture placed on the serosal surface of the small bowel. Complications such as pro-

longed post-operative ileus, mucosal or serosal tears, wound infection, air embolism and multi-organ failure have been reported (7–9).

5. Double-balloon Enteroscopy

DBE was developed in 2001 by Dr. Hironi Yamamoto (10). Its major advantage is maneuverability by a small-caliber endoscope and a flexible overtube. The smaller caliber allows for a shorter radius of curvature as well as improved maneuverability compared to colonoscopy. A latex balloon is attached to the distal end of the enteroscope. An inflated balloon on the overtube is also used to maintain a stable position while the enteroscope is advanced. Either the enteroscope balloon or the overtube balloon or both are kept inflated at all times to maintain anchorage in the intestinal tract, making steady insertion of the enteroscope possible. It can visualize the entire small bowel (by an anterograde approach or a combination of anterograde and retrograde approaches, with more success when using the combined approach). A balloon affixed to an overtube holds the bowel in place while advancing the enteroscope. A balloon affixed to the enteroscope tip anchors the scope in the deeper portion of the bowel, and the balloon overtube then advances to meet the enteroscope balloon (push procedure). The pull procedure is performed using both the enteroscope and the overtube by pulling back with both balloons inflated. During an examination, the series of maneuvers may be performed more than 12 times (11). For a retrograde approach, the ileocecal valve must be intubated by both balloons prior to further endoscopic advancement. The average time for each approach (anterograde or retrograde) is 75 min (12). DBE can be performed under conscious sedation. Studies comparing DBE and PE have shown that DBE is superior with a higher success rate for deep small bowel intubation and an increased diagnostic yield (13). The diagnostic yield using DBE is between 43 and 80% leading to a subsequent change in management in 57–84% of patients (11). Capsule endoscopy is helpful in localizing small bowel lesions prior to DBE. A retrograde DBE approach should be the initial approach when the lesion is noted to be at a location greater than 75% of the timeline of the capsule study (14). A method to measure depth of the examination was developed by May and colleagues and involves measuring the depth of insertion with each

(continued on page 14)



Figure 1. The Endo-Ease Discovery SB overtube.

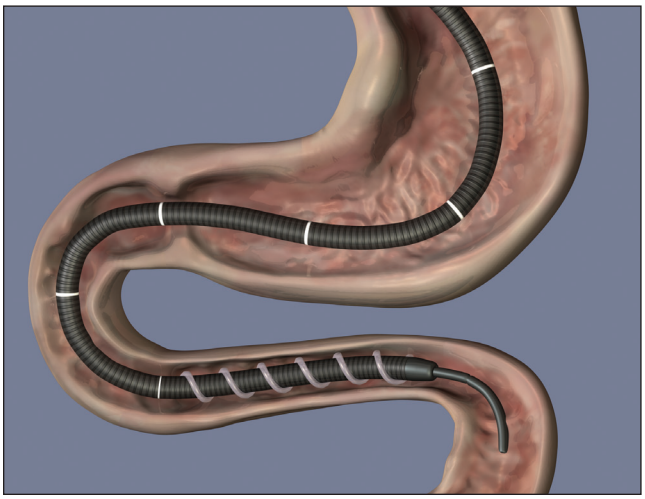

Figure 2A. Concept of "rotate to advance."



Figure 2B. Rotation pleats the small bowel.

(continued from page 12)

cycle of scope insertion and subtracting any backward slippage of the apparatus (15). The complications are abdominal pain in up to 20% of patients (16), perforation, pancreatitis (17), and bleeding (18).

6. Single Balloon Enteroscopy

SBE is a new type of balloon-assisted enteroscopy with a single balloon on the tip of the overtube but not on the enteroscope. It is similar to DBE but eliminates the step of inflating an enteroscope balloon (19). The scope tip is deflected into a U-turn to hook onto the small bowel then the overtube is advanced to the distal portion of the scope. The overtube balloon is inflated, and the enteroscope tip is subsequently returned to a luminal view. SBE was introduced in 2007, and therefore few published studies are available directly comparing SBE versus DBE. SBE is technically easier to perform and appears to provide similar diagnostic and therapeutic yield when compared with DBE. Prospective comparative studies are needed to determine if one system is superior to the other.

7. Spiral Enteroscopy

The Endo-Ease Discovery™ SB overtube (Figure 1), an FDA-approved device, facilitates endoluminal advancement through the small bowel. Although the earlier prototypes were placed over a pediatric colonoscope, the newer devices are used with enteroscopes. The insertion method concept of "rotate to advance" (Figure 2A) was developed by Spirus Medical, Inc. (Stoughton, MA). Dr. Paul Akerman was the first to propose this method for enteroscopy. The first case utilizing rotate to advance was performed in 2006 by Drs. Akerman and Cantero (20). Spiral enteroscopy can also be performed in post-gastric surgery patients, and can be used in Roux-en-Y patients requiring endoscopic retrograde cholangiopancreatography. A custom-built endotrainer was developed to assist endoscopists in estimating depths of intubation.

Technique

Spiral enteroscopy applies the mechanical advantage of a screw to convert rotational force into linear force and pleat the small bowel on the enteroscope (Figure 2B). This is a two-person procedure, with one person rotating the overtube while an endoscopist keeps the lumen in view throughout the procedure. Before performing the procedure, a proprietary lubricant is applied thoroughly to the overtube channel. When locked tightly onto the coupler at the proximal end of the overtube at the 140 cm mark, the scope is inserted into the esophagus. All subsequent movements of the scope must be done with gentle rotation of the overtube except when the overtube coupler has been unlocked. Engagement of the spiral in the duodenum may be difficult and it requires backing up of the scope and the overtube. It is passed orally using push and rotation until past the ligament of Trietz. After this, the advancement is made by clockwise rotation until the point of maximum depth of insertion. A coupler allows the Discovery SB to be fixed to the enteroscope for spiral advancement or disengaged to permit conventional manipulation of the endoscope. The enteroscope is then unlocked from the overtube and advanced through the overtube as far as possible. The enteroscope is then withdrawn using a hook and suction technique. This process is usually repeated three times. Withdrawal is performed by counterclockwise rotation of the overtube. This procedure requires total cooperation of the patient therefore deep sedation or general anesthesia is recommended. Spiral enteroscopy is faster than balloon-assisted enteroscopy. It also allows the enteroscope to be removed and reintroduced while holding the position deep in the small bowel using the spiral overtube.

Complications

In a review of 2,950 patients who underwent spiral enteroscopy, the overall severe complication rate was 0.3% (total of 9 cases; 8 cases of small bowel perforations and one case of pancreatitis) (21).

Studies

Akerman and colleagues performed the first study using Discovery SB with two types of slim 200-cm enteroscopes in 75 patients (22). Average estimated depths of insertion past the ligament of Treitz were 243 cm and 256 cm. The average times to reach the maximum depth of insertion were 18.7 and 29 minutes. The diagnostic yields were 22% and 32%. The relatively low diagnostic yield may attribute to the overall young

age of the cohort and the lack of a pre-procedural capsule endoscopy study.

Morgan and colleagues performed a prospective multicenter trial in the United States in 148 patients in 10 centers (23). Spiral enteroscopy beyond the ligament of Treitz was successful in 96% of patients. The average estimated maximum depth of insertion was 250 cm. The average time was 34 minutes for non-therapeutic procedures and 45 minutes for therapeutic procedures. There were no serious complications (pancreatitis, perforation, or death). The authors concluded that spiral enteroscopy is safe and effective and that the total procedure time and the depth of insertion compare favorably with balloon- assisted enteroscopy.

Esmail and colleagues (24) published a retrospective single center experience in 57 patients and demonstrated a 95% success rate (two procedures were unsuccessful due to sharp angulation in the stomach). The average estimated depth of insertion was 246 cm with an average total procedure time of 28 minutes. The diagnostic yield was 51%. There were no reported serious complications.

Schembre and colleagues (25) reported on a retrospective study comparing DBE and spiral enteroscopy. The diagnostic yield was similar in the two groups: DBE 70% and spiral enteroscopy 65%. The average procedure time was 77 minutes for DBE and 59 minutes for spiral enteroscopy. The conclusion was that DBE and spiral enteroscopy had similar diagnostic yield but spiral enteroscopy was faster than DBE. There were no serious complications in either group.

Buscaglia and colleagues (26) published a prospective study of the results of 90 procedures during spiral enteroscopy training. Mean insertion time was 21 minutes and mean procedure time was 34 minutes. Average estimated depth of insertion past the ligament of Treitz was 262 cm. There were no serious complications. The device was considered easy to use and operated effectively after as few as five training cases.

A retrograde small bowel evaluation is indicated in up to 40% of anterograde deep small bowel intubation cases (27). In three studies from Akerman and colleagues (28–30) for retrograde spiral enteroscopy, the average total procedure time was 29, 35, and 39 min-

Table 1.
Reported indications, endoscopic findings, and diagnostic/therapeutic interventions of spiral enteroscopy.

Reported Indications
- Abnormal capsule endoscopy
- Abnormal radiologic imaging
- Anastamotic stricture
- Celiac disease
- Chronic abdominal pain
- Chronic diarrhea
- Fistula plug placement for enterocutaneous fistula
- Hepatojejunostomy stricture
- History of intestinal polyps (familial adenomatous polyposis, Gardner's syndrome)
- Iron deficiency anemia
- Obscure-occult gastrointestinal bleeding
- Obscure-overt gastrointestinal bleeding
- Small bowel fistula
- Small bowel obstruction
- Suspected small bowel Crohn's disease
- Therapeutic ERCP after Roux-en-Y gastric bypass

Reported Endoscopic Findings
- Afferent limb syndrome
- Angiodysplasia
- Blunted villi/celiac sprue
- Diverticuli
- Erythema/inflammation
- Jejunal erosions
- Lymphangectasia/lymphangioma
- Parasite infestation (Strongyloidiasis)
- Polyps (Peutz-Jeghers syndrome)
- Portal hypertensive enteropathy
- Tumor (gastrointestinal stromal tumor, lymphoma)
- Ulcer
- Venous ectasias

Reported Diagnostic/Therapeutic Interventions
- Biliary:
  - Balloon sphincteroplasty and sludge extraction
  - Cannulation/sphincterotomy
  - Pancreatic stent placement
  - Stent removal with stricture dilation
  - Stone extraction and biliary stent placement
- Lumenal:
  - Argon plasma coagulation
  - Biopsy
  - Bipolar cauterization
  - Enteral stent placement (for malignant obstruction)
  - Fistula plug placement
  - Foreign body retrieval (percutaneous endoscopic gastrostomy tube bumper)
  - India ink tattoo
  - Polypectomy

Figure 3. Endoscopic images captured during spiral enteroscopy.

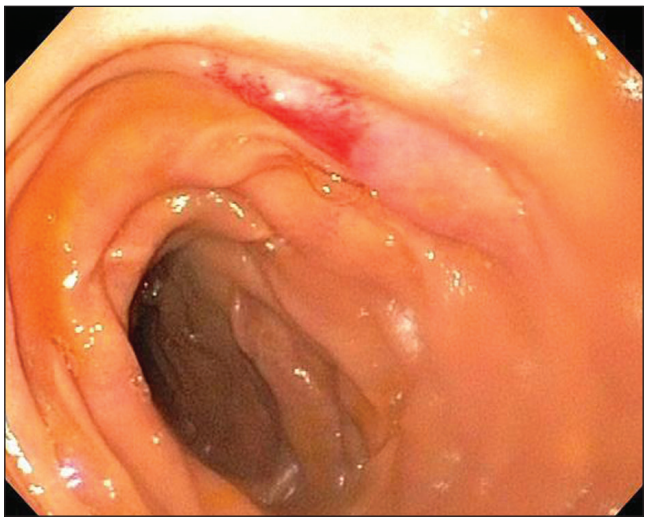

Figure 3A. Solitary jejunal angioectasia with active oozing identified on spiral enteroscopy.

utes and the estimated average depth of insertion was 113, 125, and 136 cm.

Reported Indications, Endoscopic Findings, and Diagnostic/Therapeutic Interventions of Spiral Enteroscopy

Table 1 summarizes reported indications, endoscopic findings, and diagnostic/therapeutic interventions relating to spiral enteroscopy (22–24,26,31,32). Images of endoscopic findings and interventions from two cases are shown in Figures 3A–3C. The first case presents a patient with recurrent gastrointestinal bleeding and transfusion dependent anemia, found to have multiple small bowel angioectasias on capsule endoscopy. Using spiral enteroscopy, a single 2 mm angioectasia was identified in the jejunum with a loose clot and active oozing (Figure 3A). It was successfully treated with bipolar coagulation using spiral enteroscopy and successful hemostasis was achieved (Figure 3B). The second case represents a patient that was admitted with intractable nausea and vomiting. On spiral enteroscopy, a 3 cm submucosal mass was found in the mid-jejunum with moderate intra-luminal narrowing due to the mass effect (Figure 3C) consistent with CT scan findings of a tumor with intussusception. Multiple biopsies were obtained of the lesion and sent for histopathological examination, which confirmed a lipoma.

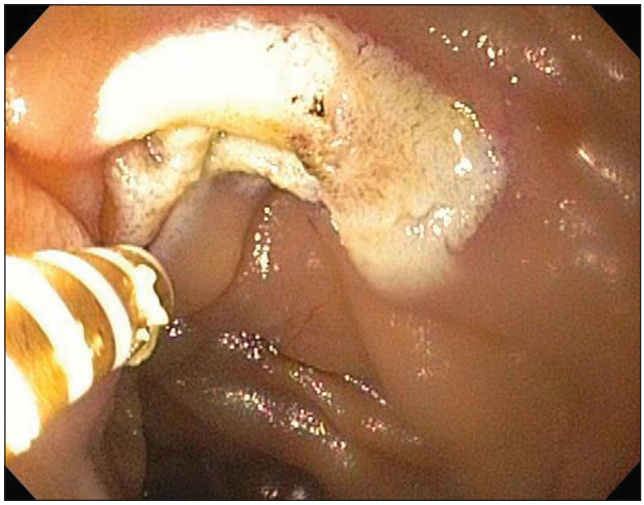

Figure 3B. Successful hemostasis following application of bipolar coagulation using spiral enteroscopy.

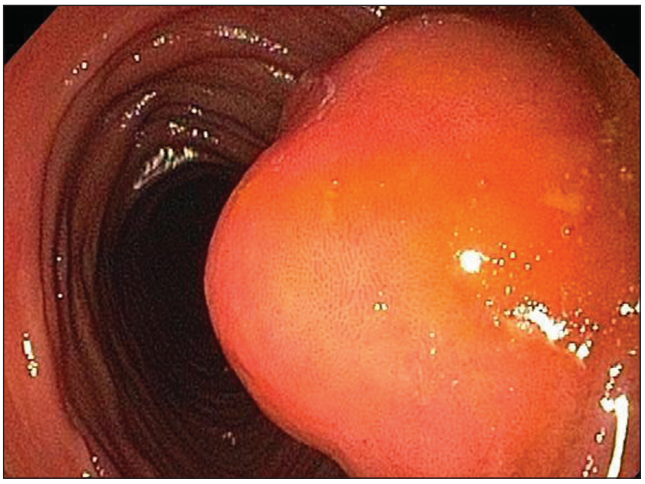

Figure 3C. Mid-jejunal submucosal mass with moderate intra-lumenal narrowing due to mass effect identified on spiral enteroscopy. Biopsies of the lesion were obtained during the procedure and subsequent histopathological examination was consistent with a diagnosis of lipoma.

SUMMARY

Spiral enteroscopy is a new technique for deep small bowel intubation. The technique is safe and effective for the detection and management of small bowel pathology. Recent studies of spiral enteroscopy have

(continued from page 16)

demonstrated diagnostic yield, total time of procedure, and depth of insertion that compare favorably with balloon-assisted enteroscopy. While spiral enteroscopy offers relatively rapid evaluation of the small bowel, future studies and device refinements will further define its role among competing technologies.

PRACTICAL POINTS

- Spiral enteroscopy is a new technique, using a spiral overtube with a colonoscope or enteroscope, that is able to completely examine the small bowel via an anterograde and/or retrograde approach
- Expanded diagnostic and therapeutic applications for small bowel pathology are now feasible due to this safe, effective, and relatively rapid technique
- Preliminary studies have demonstrated that spiral enteroscopy takes less procedure time than double balloon endoscopy and involves a short learning curve for the endoscopist. ■

References

1. Strodel WE, Eckhauser FE, Knol JA, et al. Intraoperative fiberoptic endoscopy. *Am Surg*. 1984 Jun;50(6):340-4.
2. Tada M, Akasaka Y, Misaki F, et al. Clinical evaluation of a sonde-type small intestinal fiberscope. *Endoscopy*. 1977 Mar;9(1):33-8.
3. Foutch PG, Sawyer R, Sanowski RA. Push-enteroscopy for diagnosis of patients with gastrointestinal bleeding of obscure origin. *Gastrointest Endosc*. 1990 Jul-Aug;36(4):337-41.
4. Taylor AC, Chen RY, Desmond PV. Use of an overtube for enteroscopy—does it increase depth of insertion? A prospective study of enteroscopy with and without an overtube. *Endoscopy*. 2001 Mar;33(3):227-30.
5. DiSario JA, Petersen BT, Tierney WM, et al. Enteroscopes. *Gastrointest Endosc*. 2007 Nov;66(5):872-80.
6. Sidhu R, Sanders DS, Morris AJ, et al. Guidelines on small bowel enteroscopy and capsule endoscopy in adults. *Gut*. 2008 Jan;57(1):125-36.
7. Zaman A, Sheppard B, Katon RM. Total peroral intraoperative enteroscopy for obscure GI bleeding using a dedicated push enteroscope: diagnostic yield and patient outcome. *Gastrointest Endosc*. 1999 Oct;50(4):506-10.
8. Desa LA, Ohri SK, Hutton KA, et al. Role of intraoperative enteroscopy in obscure gastrointestinal bleeding of small bowel origin. *Br J Surg*. 1991 Feb;78(2):192-5.
9. Holzman RS, Yoo L, Fox VL, et al. Air embolism during intraoperative endoscopic localization and surgical resection for blue rubber bleb nevus syndrome. *Anesthesiology*. 2005 Jun;102(6):1279-80.
10. Yamamoto H, Sekine Y, Sato Y, et al. Total enteroscopy with a nonsurgical steerable double-balloon method. *Gastrointest Endosc*. 2001 Feb;53(2):216-20.
11. Tennyson CA, Lewis BS. Enteroscopy: an overview. *Gastrointest Endosc Clin N Am*. 2009 Jul;19(3):315-24.
12. Di Caro S, May A, Heine DG, et al. The European experience with double-balloon enteroscopy: indications, methodology, safety, and clinical impact. *Gastrointest Endosc*. 2005 Oct;62(4):545-50.
13. May A, Nachbar L, Schneider M, Ell C. Prospective comparison of push enteroscopy and push-and-pull enteroscopy in patients with suspected small-bowel bleeding. *Am J Gastroenterol*. 2006 Sep;101(9):2016-24.
14. Gay G, Delvaux M, Fassler I. Outcome of capsule endoscopy in determining indication and route for push-and-pull enteroscopy. *Endoscopy*. 2006 Jan;38(1):49-58.
15. May A, Nachbar L, Schneider M, et al. Push-and-pull enteroscopy using the double-balloon technique: method of assessing depth of insertion and training of the enteroscopy technique using the Erlangen Endo-Trainer. *Endoscopy*. 2005 Jan;37(1):66-70.
16. Heine GD, Hadithi M, Groenen MJ, et al. Double-balloon enteroscopy: indications, diagnostic yield, and complications in a series of 275 patients with suspected small-bowel disease. *Endoscopy*. 2006 Jan;38(1):42-8.
17. Mensink PB, Haringsma J, Kucharzik T, et al. Complications of double balloon enteroscopy: a multicenter survey. *Endoscopy*. 2007 Jul;39(7):613-5.
18. Cheng DW, Han NJ, Mehdizadeh S, et al. Intraperitoneal bleeding after oral double-balloon enteroscopy: a case report and review of the literature. *Gastrointest Endosc*. 2007 Sep;66(3):627-9.
19. Upchurch BR, Vargo JJ. Single-balloon enteroscopy. *Gastrointest Endosc Clin N Am*. 2009 Jul;19(3):335-47.
20. Akerman PA, Cantero D. Spiral enteroscopy and push enteroscopy. Gastrointest Endosc *Clin N Am*. 2009 Jul;19(3):357-69.
21. Akerman PA, Cantero D. Complications of spiral enteroscopy in the first 2950 patients. Paper presented at: *Gastro* 2009; 2009 Nov 21-25, London, UK.
22. Akerman PA, Agrawal D, Cantero D, et al. Spiral enteroscopy with the new DSB overtube: a novel technique for deep peroral small-bowel intubation. *Endoscopy*. 2008 Dec;40(12):974-8.
23. Morgan DR, Upchurch BR, Draganov PV, et al. Spiral enteroscopy: prospective multicenter US trial in patients with small bowel disorders. *Gastrointest Endosc*. 2009;69:AB127-8.
24. Esmail S, Odstrcil EA, Mallat D, et al. A single center retrospective review of spiral enteroscopy. *Gastrointest Endosc*. 2009;69:AB197.
25. Schembre D, Ross A. Yield of double balloon versus spiral enteroscopy for obscure gastrointestinal bleeding. *Gastrointestinal Endosc*. 2009;69:AB193.
26. Buscaglia JM, Dunbar KB, Okolo PI, 3rd, et al. The spiral enteroscopy training initiative: results of a prospective study evaluating the Discovery SB overtube device during small bowel enteroscopy (with video). *Endoscopy*. 2009 Mar;41(3):194-9.
27. May A, Nachbar L, Pohl J, et al. Endoscopic interventions in the small bowel using double balloon enteroscopy: feasibility and limitations. *Am J Gastroenterol*. 2007 Mar;102(3):527-35.
28. Akerman PA, Cantero D, Pangtay J, et al. Retrograde small bowel enteroscopy using the Olympus SIF-140 260 cm enterosocpe and the Vista-SB spiral overtube. *Gastrointest Endosc*. 2009;69:AB201.
29. Cantero D, Akerman PA, Pangtay J. Retrograde spiral enteroscopy using the Fujinon EN-450T5 and Olympus SIF-180 200 cm enteroscopes with the discovery SB overtube. *Gastrointest Endosc*. 2009;69:AB192.
30. Akerman PA, Cantero D, Agrawal D, et al. Novel method of enteroscopy via anal approach using EndoEase Discovery SB overtube. *Gastro Endosc*. 2007;65(5):AB277.
31. Riccioni ME, Cianci R, Spada C et al. Use of spiral enteroscopy in a tertiary endoscopy center: initial experience. *Endoscopy*. 2009 Sep;41(9):820.
32. Shin EJ. Enteral stent placement using spiral enteroscopy for malignant mid-jejunal obstruction. T*he Dave Project* 2009.