

Fellows' Corner

by Justin Chen, Kheng-Jim Lim, Arkady Broder

CASE PRESENTATION

A 53-year-old Asian male with a history of chronic hepatitis B presents to a university hospital with jaundice for seven days. Prior to admission, he had intermittent post-prandial right upper quadrant discomfort, nausea, vomiting and jaundice and was evaluated by his primary care physician. An outpatient abdominal ultrasound found a 2 cm common bile duct (CBD) stone and a dilated CBD up to 13 mm. He did not have any fevers or abdominal pain. His only medication was entecavir for chronic hepatitis B. His vital signs were within normal limits, physical exam was notable for jaundice, a benign abdomen and Murphy's and Courvoisier's sign were not present. Laboratory studies were significant for alkaline phosphate (ALP) 138 U/L, aspartate and alanine aminotransferase (AST, ALT) 34, 79 IU/L, respectively, total bilirubin 14.6 mg/dL, lipase 24 U/L, CA 19-9 of 2910 U/mL, and white blood cell count (WBC) 5,500 cell/ μ L. Endoscopic ultrasound found choledocholithiasis and CBD dilation. Endoscopic retrograde cholangiopancreatography (ERCP) with sphincterotomy was performed and an exudate was seen in Figure 1. Subsequently, cannulation of the ampulla demonstrated the findings in Figure 2.

Justin Chen, Medical Student, Drexel University College of Medicine. Kheng-Jim Lim MD, Gastroenterology Fellow, Robert Wood Johnson Medical School, Rutgers University. Arkady Broder MD, Gastroenterology Saint, Peter's University Hospital

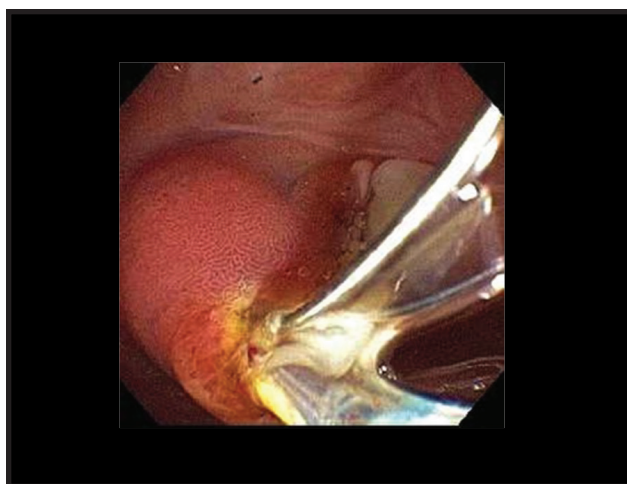


Figure 1. Endoscopic capture of exudate after sphincterotomy

1. What is the diagnosis?
2. What is the substance exuding from ampulla?
3. What are the therapeutic options?
4. What other associated illnesses need to be investigated and how?

(continued on page 76)

(continued from page 74)

This is a 53-year-old male with a clinical presentation, laboratory values, and imaging suggesting choledocholithiasis but on ERCP had a diagnosis of Mirizzi syndrome (MS). Upon contrast injection, ERCP revealed contrast dye only filling the cystic duct and the guide wire in the CBD (Figure 2). Further manipulation confirmed a gallstone within the cystic duct compressing the CBD (Figure 3).

Mirizzi syndrome is a complication of gallstone disease that involves obstruction of the CBD by a stone in the cystic duct. It is more predominant in women, ages 53-70 years old, with a 0.2-1.5% prevalence in individuals with gall bladder disease. There is an increased prevalence in individuals with anatomical abnormalities of the biliary tree, like the long cystic duct with low insertion of cystic duct seen in this patient.¹ The most popular classification for MS involves four types described by Csendes in 1989.² Type I: external compression of CBD due to a stone impacted at the neck of the gallbladder or at the cystic duct. Type II: presence of a cholecystobiliary fistula that affects less than 1/3 of the circumference of the CBD. Type III: presence of a cholecystobiliary fistula with erosion of the CBD that involves up to 2/3 of its circumference. Type IV: presence of a cholecystobiliary fistula with complete destruction of the entire wall of the CBD.³

MS is often misread on transabdominal ultrasound and magnetic resonance cholangiopancreatography (MRCP) as choledocholithiasis and is ultimately diagnosed with ERCP. Transabdominal ultrasound is found to be diagnostically accurate in 29% of cases with a sensitivity of 8.3-27%. Transabdominal ultrasound classically shows dilatation of biliary system proximal to the stone and normal width of the CBD distal to the stone. MRCP has a diagnostic accuracy of 50% and can show external compression of the CBD and visualize a fistula if present for staging. ERCP can confirm or diagnose MS with a diagnostic accuracy of 55-90%. ERCP with stent placement and sphincterotomy is often performed as therapy for symptoms of jaundice and ascending cholangitis.¹

Prolonged cholestasis in this patient led to the development of "milk of calcium" or "limy bile" exuding from the ampulla after sphincterotomy. Although the pathophysiology of "milk of calcium" is not completely understood, it is believed that obstruction of the gall bladder neck, cystic duct or CBD with subsequent biliary stasis leads to precipitation of calcium carbonate

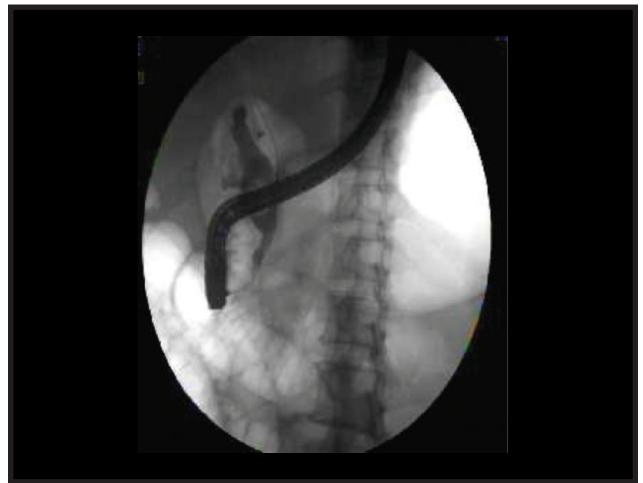

Figure 2. Fluoroscopic image during ERCP

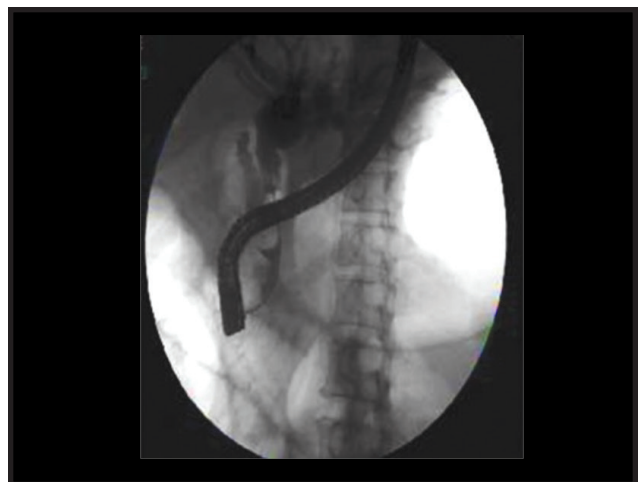

Figure 3. Fluoroscopic image of biliary tree during ERCP

crystals in the bile. The exudate manifests as a thick, radiopaque paste in the gallbladder or common bile duct.⁴ MS is typically diagnosed on imaging, including abdominal X-rays and CT scan, which shows filling of the gallbladder or CBD as if contrast was administered. Prevalence of limy bile syndrome ranges between 0.1-1.7% of all surgeries for cholelithiasis with a male to female ratio of 1:3.⁵

The treatment for MS is typically surgical and the pre-operative diagnosis may not always be known prior to surgery. Surgical treatment options are determined by the classification of MS. Open cholecystectomy is usually performed due to inflammation that cause adhesions and distorts the anatomy increasing risk of biliary tree injury.¹ Laparoscopic surgery is

controversial and reserved for Type I MS because of a high laparoscopic to open conversion and complication rate. Type I MS can be treated with total or subtotal cholecystectomy with stone extraction. Treatment for Type II MS is dependent on fistula size and can involve partial cholecystectomy, suture repair or T tube placement to repair the fistula. Type III can be treated with choledochoplasty or enterobiliary anastomosis with cholecystectomy and Type IV MS requires cholecystectomy and enterobiliary anastomosis, most commonly Roux-en Y hepaticojejunostomy.² Stone removal can be attempted with ERCP using stone removal techniques (e. g. balloon, basket, lithotripsy), but it is reserved for patients who are poor surgical candidates due to increased risk of bleeding and perforation.¹

In patients with MS, it is necessary to evaluate for gallbladder cancer preoperatively with imaging or a CA19-9 level, intraoperatively, or post operatively with pathology. Gallbladder cancer is present in 5.3%-27.8% of patients with MS compared to 1-2% in patients with benign biliary disease.⁶ The underlying chronic cholestasis found in MS is proposed to be the risk factor for gallbladder cancer.⁷ Although the average CA19-9 is 987 units/ml in patients who had both MS and gallbladder cancer, 4.7% of patients who had cholangitis or cholestasis with no gallbladder cancer had CA19-9 levels >1000 units/ml.^{7,8}

As in many patients with MS, this patient was misdiagnosed initially with transabdominal ultrasound and EUS as choledocholithiasis, but later found to have MS on ERCP. An MRCP later showed no fistula and confirmed Type I MS and an open partial cholecystectomy was then performed. Post operatively, a partial gallbladder pathology showed no malignancy with evidence of chronic cholecystitis and his CA19-9 decreased from 2910 U/mL to 19 U/mL. The patient was subsequently discharged from the hospital in good health. ■

References

1. Beltrán MA. Mirizzi syndrome: history, current knowledge and proposal of a simplified classification. *World J Gastroenterol.* 2012 Sep 14;18(34):4639-50.
2. Lledó JB, Barber SM, Ibañez JC, Torregrosa AG, Lopez-Andujar R. Update on the diagnosis and treatment of mirizzi syndrome in laparoscopic era: our experience in 7 years. *Surg Laparosc Endosc Percutan Tech.* 2014 Dec;24(6):495-501.
3. Csendes A, Díaz JC, Burdiles P, Maluenda F, Nava O. Mirizzi syndrome and cholecystobiliary fistula: a unifying classification. *Br J Surg.* 1989 Nov;76(11):1139-43.
4. Ballas KD, Alatsakis MB, Rafailidis SF, Psarras K, Sakadamis AK. Limy bile syndrome: review of seven cases. *ANZ J Surg.* 2005 Sep;75(9):787-9.
5. Itoh H. Management of limy bile syndrome: no therapy, laparotomy or endoscopic treatment? *Intern Med.* 2003 Jan;42(1):1-2.
6. Redaelli CA, Büchler MW, Schilling MK, Krähenbühl L, Ruchti C, Blumgart LH, Baer HU. High coincidence of Mirizzi syndrome and gallbladder carcinoma. *Surgery.* 1997 Jan;121(1):58-63.
7. Prasad TL, Kumar A, Sikora SS, Saxena R, Kapoor VK. Mirizzi syndrome and gallbladder cancer. *J Hepatobiliary Pancreat Surg.* 2006;13(4):323-6.
8. Robertson AG, Davidson BR. Mirizzi syndrome complicating an anomalous biliary tract: a novel cause of a hugely elevated CA19-9. *Eur J Gastroenterol Hepatol.* 2007 Feb;19(2):167-9.

Fellows' Corner

is open to Trainees and Residents only.

Section Editor:

C.S. Pitchumoni, M.D.

- Send in a brief case report.
- No more than one double-spaced page.
- One or two illustrations, up to four questions and answers and a three-quarter to one-page discussion of the case.
- Case to include no more than two authors.

Case should be e-mailed to:

C. S. Pitchumoni, M.D.
pitchumoni@hotmail.com