

Fellows' Corner

by Phillip Goldstein, Nyree Thorne
assisted by Kavita Kongara and Douglas Katz

H&P/LABS

A thirty-two year old male presented with worsening lower abdominal pain over the last two weeks. He described the pain as intermittent, non-radiating and diffuse. The pain had been associated with 2–3 episodes of diarrhea and more recently four episodes of vomiting. The pain also seemed to intensify with meals.

The patient described a similar discomfort that although intermittent and less intense had persisted over the past year and a half. The patient did not report any fever, chills, night sweats, hematemesis, melena, or hematochezia. Review of systems was negative for weight loss, cough, chest pain and rashes.

The patient's past medical history was significant for allergic rhinitis, and he did not report any prior surgeries. His medications included Nexium and Allegra at home. The patient has resided in the United

States for several years, but often traveled to India with the last trip having been six months previous.

On physical exam, the patient was afebrile, all other vital signs were stable. Skin was of normal pigmentation, no rashes or bruises were apparent. On abdominal exam, the patient had decreased bowel sounds, the abdomen was soft, and tender to deep palpation in the lower left and right quadrants. There was

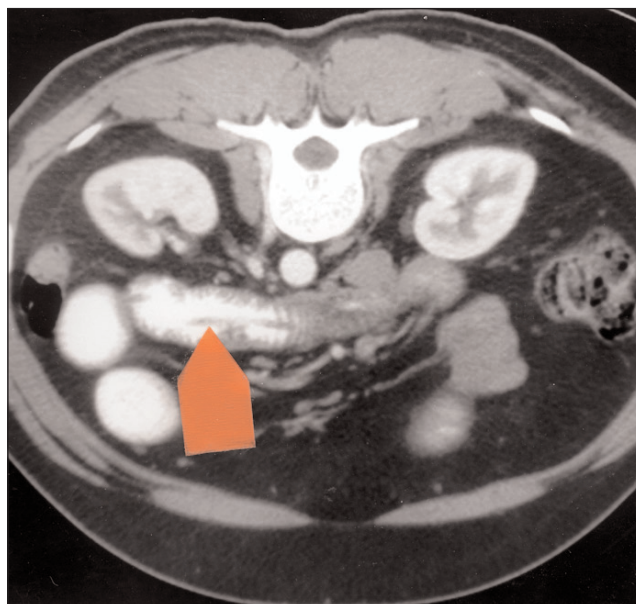


Figure 1.

Phillip Goldstein, M.D., Resident, Internal Medicine and Nyree Thorne, M.D., Fellow, Gastroenterology both at Winthrop University Hospital Mineola, NY. Assisted by Kavita Kongara, M.D., Assistant Professor of Medicine, SUNY at Stony Brook, Stony Brook, NY and Director of Gastrointestinal Diagnostic Motility Center, Winthrop University Hospital, Mineola, NY and Douglas Katz, M.D., Vice Chairman of Clinical Research and Education, Radiology Department, Winthrop University Hospital, Mineola, NY.

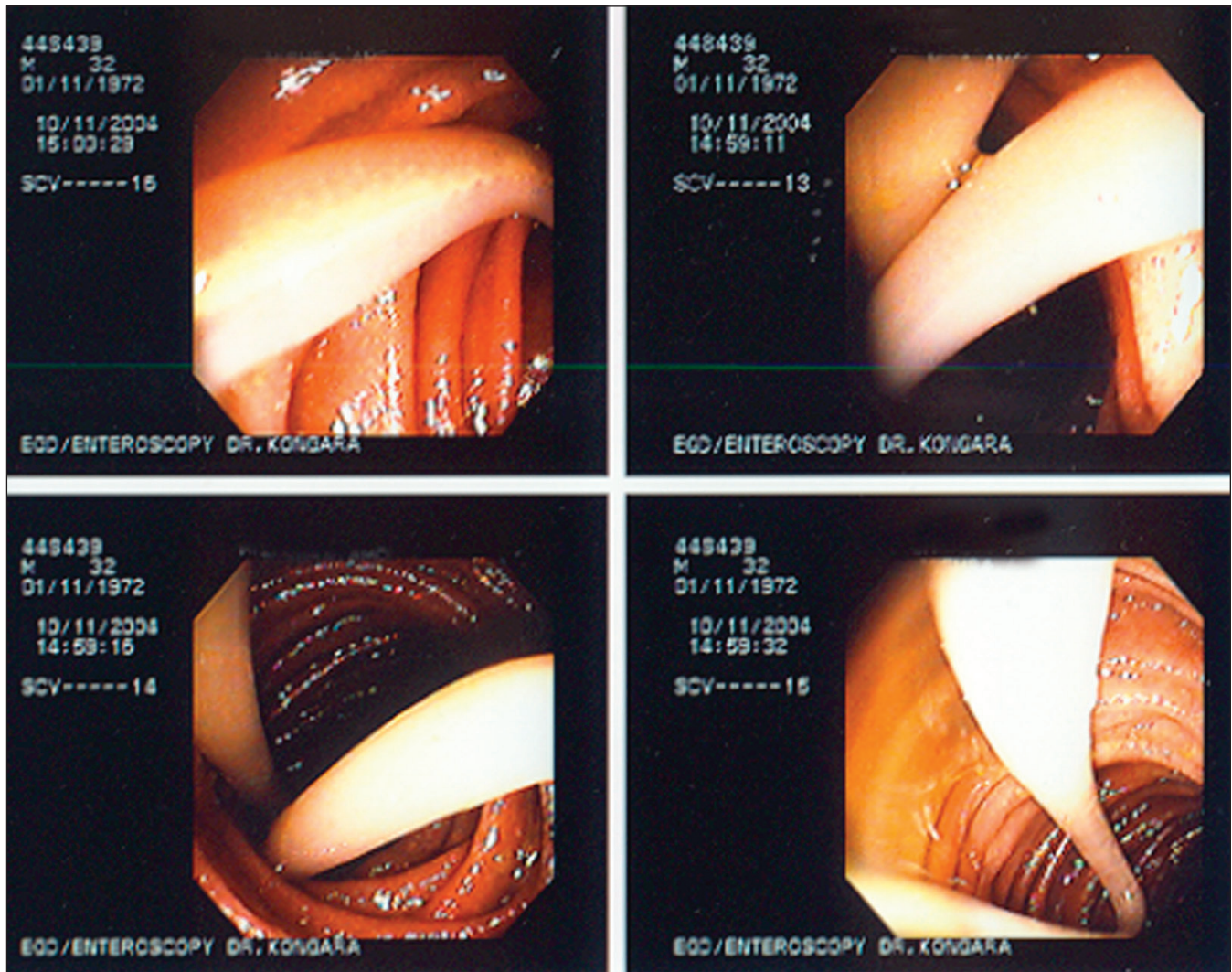


Figure 2.

no distention, rebound tenderness, guarding and no masses were palpated. Rectal exam revealed guaiac negative brown stool with normal sphincter tone and no masses. The remainder of the physical exam was otherwise normal.

Lab results on admission showed a WBC of 10, the differential included Poly's-37%, Lymph-36%, Mono-6% and Eos-21%. Hemoglobin, hematacrit and platelets were normal. The computed tomography scan of the abdomen and pelvis with contrast revealed proximal distended loops of small bowel filled with fluid and increased wall thickening. There was RUQ lymphadenopathy and no abscesses were present. The

images revealed an elongated structure within the lumen of the jejunum (Figures 1 and 2).

Questions

1. What is the diagnosis given the above history, physical findings and images?
2. How are the hosts infected and who is most at risk?
3. What are the most serious complications of this parasite?
4. How is it diagnosed?
5. What is the mainstay of treatment?

(Answers and Discussion on page 107)

(continued from page 91)

The patient was then taken for enteroscopy, which exposed a large worm with the typical appearance of *Ascaris lumbricoides*.

DISCUSSION

Ascariasis

It is estimated that 1.4 billion worldwide are infected with *Ascaris lumbricoides*, the largest intestinal round-worm or nematode to infect humans. The nematodes are either white or pink colored, about six millimeters in diameter, are tapered at both ends, and can measure up to almost 40 cm long. They are most prevalent in children ages 2–10 and in areas deficient in safe sanitation practices. *Ascaris* infection is also more common in tropical regions where the warm, wet climate provides a year round environment that is optimal for transmission. Ova are thought to be able to survive in such conditions for up to 10 years. In the United States with the introduction of modern sanitation practice the prevalence dropped drastically and is currently estimated that less than 2% of stool samples are positive for *A. lumbricoides*.

Transmission occurs via the ingestion of water or uncooked food containing the ova of the parasite. The oval ova, with their thick shell and mamillated outer

coat, release the larvae in the intestines. The larvae then penetrate the intestinal walls and migrate hematogenously or through the lymphatic system to the lungs mainly, but also to the kidney, heart and brain. Within the alveoli the larvae mature over a short period of 10 days before passing up the bronchi and trachea to reach the esophagus and are swallowed once again. In the intestine the worms can grow substantially where females may reach up to 18 inches in length (males slightly shorter). In two to three months the female will produce numerous ova to be excreted by the host and the cycle is completed.

Clinically, the majority of individuals infected are asymptomatic. However, when symptoms are present they are usually related to the larval migration stage or the mature adult worm stage. The symptoms and complications of infection are broken down into three categories:

1. Pulmonary and hypersensitivity manifestations,
2. Intestinal symptoms and obstruction, and
3. Hepatobiliary and pancreatic symptoms.

Respiratory symptoms occur only in a sensitized host during the larval stage of migration and present as a hypersensitivity pneumonitis (Lofflers syndrome). As in the case discussed here, intestinal symptoms usually only arise with profound infection. Symptoms

VISIT OUR WEB SITE AT
WWW.PRACTICALGASTRO.COM

Fellows' Corner is a New Section in *Practical Gastroenterology*
open to Trainees and Residents ONLY.

Section Editors: C. S. Pichumoni, M.D. and K. Shiva Kumar, M.D.

Send in a brief case report. No more than one double-spaced page. One or two illustrations, up to four questions and answers and a three-quarter to one-page discussion of the case. Case to include no more than two authors. A \$100.00 honorarium will be paid per publication.

Case should be sent to:
C. S. Pichumoni, M.D.,
Chief, Gastroenterology, Hepatology
and Clinical Nutrition
St. Peter's University Hospital
254 Easton Avenue, Box 591
New Brunswick, NJ 08903

or
K. Shiva Kumar, M.D.
Ochsner Clinic
Division of Gastroenterology
1514 Jefferson Highway
New Orleans, LA 70121

include abdominal discomfort, anorexia, nausea, vomiting and occasionally diarrhea thought to be due to impaired absorption of dietary proteins, lactose and vitamin A.

Intestinal obstruction is the leading cause of complications of ascariasis infection accounting for over 70% of all complications. The site of obstruction is most often the ileocecal valve with the highest percentage of cases occurring in children ages one through five. In some endemic areas, obstruction due to *A. lumbricoides* is the most common cause of acute abdominal surgical emergencies. Patients usually present with colicky abdominal pain, vomiting (which may contain worms) and constipation, which is a very similar picture to the presentation of the patient above.

Hepatobiliary and pancreatic symptoms arise when the adult worms migrate up through the biliary tree causing biliary colic, acalculous cholecystitis, ascending cholangitis, obstructive jaundice or even a common bile duct perforation and hepatic abscesses.

Stool microscopy is the usual method with ova appearing on direct examination of feces or after a concentrating technique. However, the eggs won't typ-

ically appear in the stool until 40 days post infection. Diagnosis of Ascariasis in our patient involved a high index of suspicion as well as the unusual findings of the CT of the abdomen.

Occasionally, a mass of worms can be seen on abdominal films as the mass contrasts against the gas in the bowel creating a whirlpool effect. Barium studies may also show elongated filling defects in the intestine or a white thread coursing the worms body due to ingestion of barium by the worm.

Ultrasound studies are useful for hepatobiliary and pancreatic ascariasis, along with CT and MRI which will image the worm in cross section in the duct and give a bull's eye appearance. ERCP is another procedure to diagnose ascariasis as well as a method to remove the worm.

Finally, serology studies, particularly IgG antibodies to ascaris can be detected but are generally reserved for epidemiologic studies since the antibodies to ascaris can cross-react with antigens from other parasites.

Treatment can consist of any one of a number of antihelmintics. A single dose of Albendazole 400 mg is almost 100% effective. Mebendazole, either 100 mg twice daily for three days or a single dose of 600 mg is approximately 95% effective and Albendazole and Mebendazole are the current mainstays of treatment. Pyrantel pamoate is used in pregnancy and other acceptable treatment options include Ivermectin, Piperazine citrate and Levamisole. ■

References

1. Khuroo MS. Ascariasis. *Gastroenterol Clin N Amer*, 1996; 25:553.
2. Reeder NM. The radiological and ultrasound evaluation of ascariasis of the GI, biliary, respiratory tracts. *Semin Roentgenol*, 1998; 33:57.
3. Seltzer E. Ascariasis. *Tropical Infectious Diseases: Principles, Pathogenesis and Practice*. 1st ed., Guerrant RL, Weiler PF, Philadelphia: Churchill Livingstone; 199:553.

PRACTICAL GASTROENTEROLOGY

REPRINTS

Practical Gastroenterology reprints are valuable, authoritative, and informative. Special rates are available for quantities of 100 or more.

For further details on rates or to place an order:

Practical Gastroenterology

Shugar Publishing

99B Main Street

Westhampton Beach, NY 11978

Phone: 631-288-4404 Fax: 631-288-4435

www.practicalgastro.com

There isn't a physician who hasn't had at least one "Case to Remember" in his career. Share that case with your fellow gastroenterologists.

Send it to Editor: *Practical Gastroenterology*, Shugar Publishing, 99B Main Street, Westhampton Beach, NY 11978. Include any appropriate illustrations. Also, include a photo of yourself.