

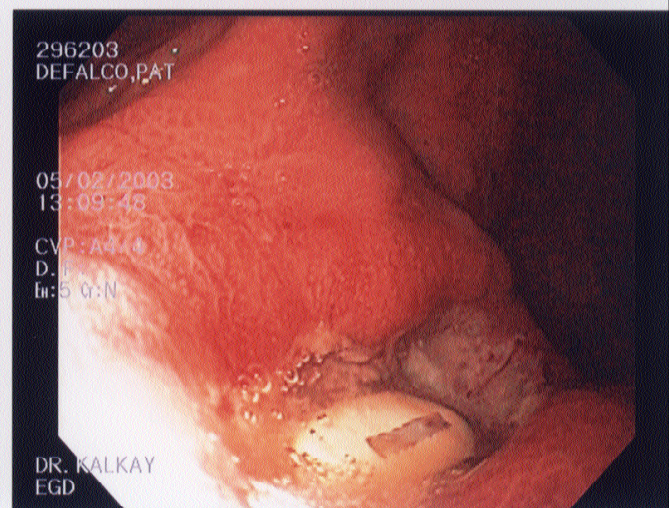
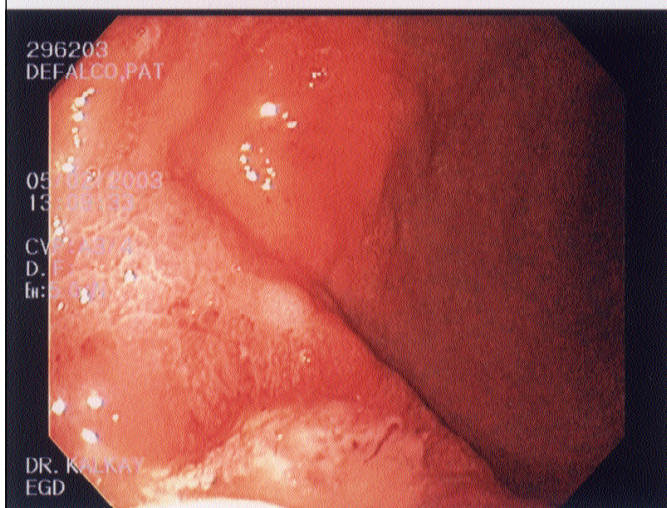
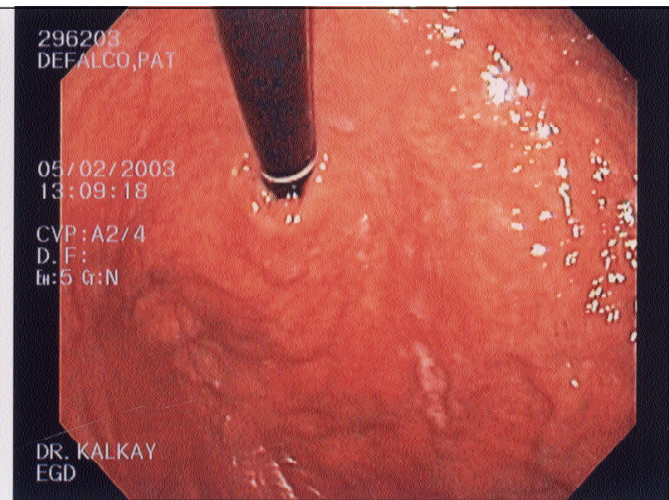
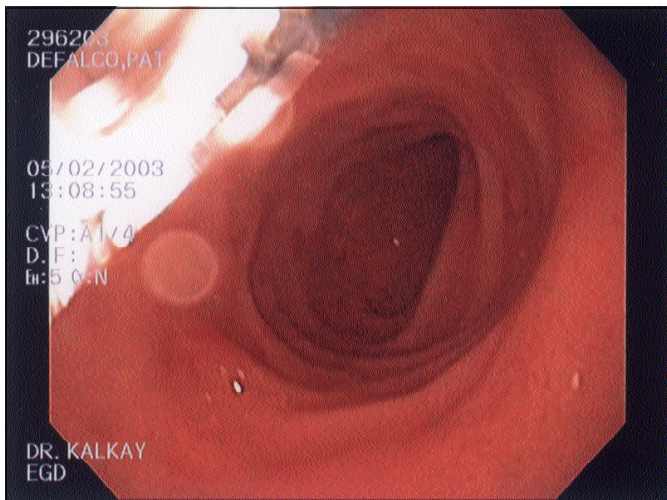
# It's More Than Just a Pretty Picture

by M. Nuri Kalkay

**A** 76-year-old white male presented to the emergency room with tarry stools of three-day duration. The following morning, an urgent EGD showed the following endoscopic image.

**What is your diagnosis?**

*Look at page 56 for the answer.*



M. Nuri Kalkay, M.D., Director of Endoscopic Services, Bayshore Community Hospital, Holmdel, NJ.